

## Lingual Tonsillectomy Using Bipolar Radiofrequency Plasma Excision

Sam Robinson, MB, BS, FRACS, Sandra L. Ettema, MD, PhD, Laura Brusky, MD, and B. Tucker Woodson, MD, FACS, Adelaide, Australia; and Milwaukee, Wisconsin

Journal of Otolaryngology–Head and Neck Surgery (2006) 134, pp. 328–330

### OBJECTIVE

The authors describe a method to remove lingual tonsils using Coblation. They indicate that Coblation generates a plasma field in saline irrigation and causes minimal tissue trauma, decreased intra-operative bleeding and char formation, and minimized postoperative pain. The Wands ease of use, malleability, (EVac 70), and ability to work outside the lumen of the laryngoscope allowed for removal of tissue that would be extremely difficult to remove using laser or other techniques.

### DESIGN

Ten lingual tonsillectomies for modest lingual tonsil hypertrophy (LTH) and 8 for massive LTH were performed.

In this study, the authors recommend using a suspension rigid laryngoscope or Weerda bivalved laryngoscope to expose the valleculae. A standard microlaryngoscopy with an operating microscope magnifies the field and allows precise delineation of the depth of dissection. The laryngoscope is slowly withdrawn until the foramen cecum is identified, which is the anterior, midline limit of dissection. Optimum dissection is obtained by bending the malleable wand approximately 30° and inserting the probe between the corner of the mouth and outside of the laryngoscope, with the tip of the probe being visualized in the operative field beyond the tip of the laryngoscope (Fig 1).

## CLINICAL TECHNIQUES AND TECHNOLOGY

# Lingual Tonsillectomy Using Bipolar Radiofrequency Plasma Excision

**Sam Robinson, MB, BS, FRACS, Sandra L. Ettema, MD, PhD, Laura Brusky, MD, and B. Tucker Woodson, MD, FACS, Adelaide, Australia; and Milwaukee, Wisconsin**

**H**ypertrophic lingual tonsils may obstruct the retrolingual airway. In many patients, exposure and removal of lingual tonsils is difficult. This is particularly true of obstructive sleep apnea (OSA) patients. We describe a method to remove lingual tonsils using a bipolar radiofrequency probe or coblation. This tool generates a plasma field in saline irrigation and causes minimal tissue trauma, decreases intraoperative bleeding and char formation, and minimizes postoperative pain. Its ease of use, malleable probe, and ability to work outside the lumen of the laryngoscope allow removal of tissue that would be extremely difficult to remove using laser or other techniques.

## MATERIALS AND METHODS

A review and approval of the protocol by the Froedtert Memorial Lutheran Hospital/Medical College of Wisconsin Institutional Review Board was completed before this investigation. Our method for removing lingual tonsils using a bipolar radiofrequency probe or coblation is described. After the administration of general nasotracheal anesthesia, either a suspension rigid laryngoscope or Weerda (Karl Storz, Tuttlingen, Germany) bivalved laryngoscope exposes the valleculae. A standard microlaryngoscopy with an operating microscope (400-mm objective lens) magnifies the field and allows precise delineation of the depth of dissection. An Evac 70 tonsil and adenoid coblation wand with a coblator II generator (setting 7-9; Arthrocare Corp, ENTec Division, Sunnyvale, CA) hemostatically excises lymphoid tissue with continuous irrigation and suction. The laryngo-

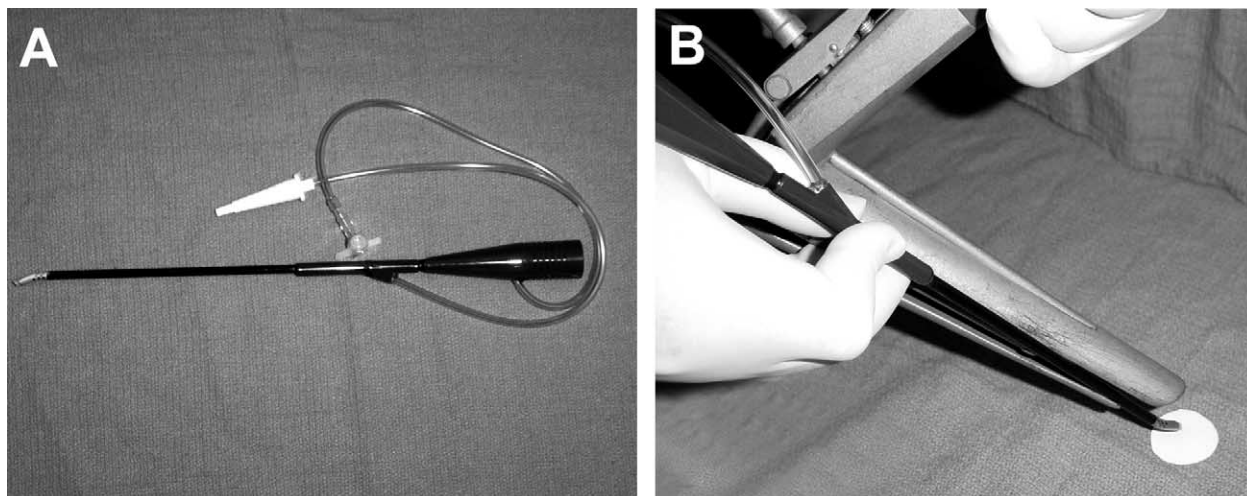
scope is slowly withdrawn until the foramen cecum is identified, which is the anterior, midline limit of dissection. Optimum dissection is obtained by bending the malleable wand approximately 30° and inserting the probe between the corner of the mouth and outside of the laryngoscope, with the tip of the probe being visualized in the operative field beyond the tip of the laryngoscope (Fig 1). Counter pressure over the hyoid region augments exposure. The wand tip may also be placed between the leaves of a bivalved laryngoscope to allow access to unreachable areas. As the probe tip is orientated upward, a pressure irrigation bag delivers a continuous stream of fluid onto the operative field against gravity. This eliminates problems of charring. The coblator II regulates the flow of irrigation to only occur with coblation activation, and, therefore, the volume of irrigation fluid flowing into the pharynx is not excessive. Bleeding vessels not sealed during coblation tissue removal are controlled with the coagulation mode of the machine.

## RESULTS

Ten lingual tonsillectomies for modest lingual tonsil hypertrophy (LTH) and 8 for massive LTH have been performed. For modest LTH, operative time varied from 10 to 30 minutes and an average time of 1 hour and 54 minutes for massive LTH. Objectively measured postoperative inpatient pain scores ranged from 0 to 7 (average of 3) on a visual analog scale from 0 to 10. Patients were discharged with a 7- to 10-day prescription for a narcotic such as hydrocodone/acetaminophen (5/500). Retrospectively, outpatients reported

From Private Practice, Adelaide, Australia (Dr Robinson); and Department of Otolaryngology and Communications Science, Medical College of Wisconsin, Milwaukee, WI (Drs Ettema, Brusky, and Woodson).

Reprint requests: B. Tucker Woodson, MD, FACS, Medical College of Wisconsin, 9200 West Wisconsin Avenue, Milwaukee, WI 53226.  
E-mail address: bwoodson@mcw.edu



**Figure 1** (A) Tonsil and adenoid malleable coblation wand. (B) Placement of the coblation wand outside the lumen of the Weerdal laryngoscope for dissection of the lingual tonsil.

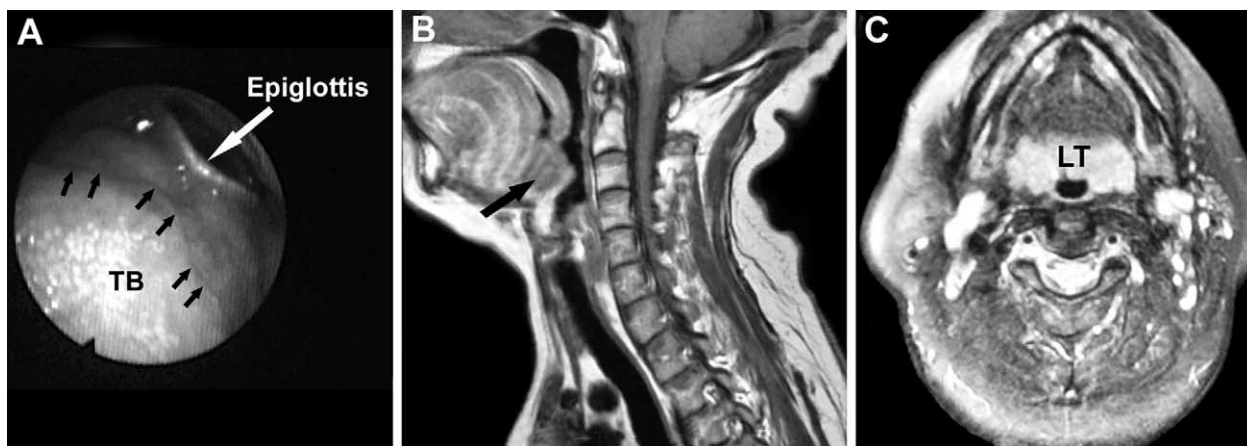mild to sometimes moderate pain lasting approximately 7 to 10 days. There have been no reactive or secondary bleeds to date in this small series. Estimated blood loss during the procedures ranged from approximately 0 to 50 mL with an average of 20 mL. None of the patients required tracheostomy tube placement or had airway problems postoperatively. Three patients had a transient change in taste, which fully resolved at the 3-month follow-up. Only 2 of these patients have been revised requiring additional removal of lingual tonsils.

## DISCUSSION

A variety of techniques have been described in the literature for lingual tonsillectomy. These include sharp dissection, laser,<sup>1,2</sup> suction diathermy,<sup>3</sup> cryotherapy,<sup>4</sup> and an ultrasonic

coagulating dissector.<sup>5</sup> Laser techniques that have been described are expensive, carry a small risk of airway fire, and the dissection is slower compared with the coblation technique. Suction diathermy chars tissue, and cryotherapy yields unpredictable results. Lingual tonsillectomy is often extremely difficult to perform. Classical approaches using a tonsillectomy gag often do not provide a good access to the valleculae. The alternative of laryngoscopic visualization is difficult particularly in OSA patients. This new technique allows laryngoscopic visualization of the lingual tonsils, use of a curved instrument, lack of char, and excellent hemostasis.

The reduced morbidity of the device expands the potential indications for lingual tonsillectomy. Aside from massive hypertrophy, patients with OSA may be candidates if the bulk of the lingual tonsils obscure visualization of the root of the epiglottis/valleculae on supine awake nasoendo-



**Figure 2** (A) Bulk of the lingual tonsils obscure visualization of the root of the epiglottis/valleculae on nasoendoscopic examination. Black arrows delineate border of lingual tonsils and tongue base (TB). (B) Sagittal MRI depicting enlarged lingual tonsils (black arrow) filling the vallecular space and tipping the epiglottis posteriorly. (C) Contrast-enhanced axial MRI depicting highlighted region of lingual tonsils (LT) obstructing the airway.

scopic examination (Fig 2A). If it is difficult to assess their lingual tonsillar anatomy via nasoendoscopic examination and clinically we suspect enlarged lingual tonsils, then magnetic resonance imaging (MRI) of the neck (to highlight the lymphoid tissue) with and without contrast is obtained (Fig 2B and C).

With this technique, the surgeon's learning curve continues to progress with regard to amount of tissue removal. Because of inadequate exposure, lingual tonsils may be left laterally and 2 patients in this series required revision procedures for this.

## CONCLUSION

We present a direct and improved technique for lingual tonsillectomy. In addition to treating isolated lingual tonsil

enlargement, it may also be a valuable adjunct to upper-airway reconstruction techniques in OSA.

## REFERENCES

1. Krespi YP, Har-El G, Levine TM, et al. Laser Lingual tonsillectomy. *Laryngoscope* 1989;99:131–5.
2. Wouters B, van Overbeek JJM, Buitter CT, et al. Laser surgery in lingual tonsil hyperplasia. *Clin Otolaryngol* 1989;14:291–6.
3. Yoskovitch A, Samaha M, Sweet R. Suction cautery use in lingual tonsillectomy. *J Otolaryngol* 2000;29:117–8.
4. Wouters B, van Overbeek JJM, Hoeksema PE. Laser surgery in lingual tonsil hyperplasia. *Clin Otolaryngol Allied Sci* 1989;14:291–6.
5. Suzuki K, Kawakatsu K, Hattori C, et al. Application of lingual tonsillectomy to sleep apnea syndrome involving lingual tonsils. *Acta Otolaryngol* 2003;550(suppl):65–71.

## RESULTS

<b>Operating Time</b>	For modest LTH, operative time varied from 10 to 30 minutes and an average time of 1 hour and 54 minutes for massive LTH.
<b>Postoperative Pain</b>	Postoperative inpatient pain scores ranged from 0 to 7 (average of 3) on a VAS from 0 to 10. Patients were discharged with a 7 to 10 day prescription for a narcotic such as hydrocodone/acetaminophen.
<b>Complications</b>	<p>No reactive or secondary post-op bleeds</p> <p>None of the patients required tracheostomy tube placement or had airway problem post-op.</p> <p>Three patients had a transient change in taste, Which fully resolved at the 3-month f/u. Only 2 of these patients have been revised requiring additional removal of lingual tonsils.</p>
<b>Blood Loss</b>	EBL ranged from approximately 0 to 50 mL with an average of 20 mL.
<b>Learning Curve</b>	With this technique, the surgeon's learning curve continues to progress with regard to amount of tissue removal. Because of inadequate exposure, lingual tonsils may be left laterally and 2 patients in this series required revision procedures.

## Discussion

Lingual tonsillectomy is often extremely difficult to perform. Classical approaches using a tonsillectomy gag often do not provide a good access to the valleculae. The alternative of laryngoscopic visualization is difficult particularly in OSA patients. This new technique allows laryngoscopic visualization of the lingual tonsils, use of a curved instrument, lack of char, and excellent hemostasis. The reduced morbidity of the device expands the potential indications for lingual tonsillectomy.

In addition to treating isolated lingual tonsil enlargement, the authors state that Coblation may also be a valuable adjunct to upper airway reconstruction techniques in OSA.