

Radiofrequency ablation (coblation): a promising new technique for laryngeal papillomata

M S TIMMS, I A BRUCE, N K PATEL*

Abstract

This paper describes a new application for radiofrequency ablation in head and neck surgery. Two patients with extensive laryngeal papillomata were successfully treated using this technology. The technique is described in detail, highlighting the main benefits of this approach as compared with existing techniques. These advantages include limited damage to underlying tissues and a bloodless field.

Key words: Papilloma; Laryngeal Neoplasms; Radiofrequency Ablation; Otolaryngologic Surgical Procedures

Introduction

Laryngeal papillomatosis is an uncommon condition, affecting 1:100 000 of the population per annum.¹ Although relatively uncommon, laryngeal papillomatosis is a potentially life-threatening condition associated with considerable functional disability, in particular, airway obstruction and dysphonia. Treated laryngeal papillomata often recur, requiring multiple procedures, which tends to result in scarring of the larynx.² The current trend is away from radical clearance of all disease towards conservative clearance, maintaining a reasonable voice and airway while awaiting eventual spontaneous cure, presumed to be mediated by the patient's immune system.³

To date, various surgical treatments have used: cold steel dissection, suction diathermy, CO₂ and other lasers, and the microdebrider.⁴ All the above modalities have their own disadvantages, including bleeding, scarring, complexity and expense.^{5–9} Laryngeal surgeons remain on the lookout for a modality that allows clean, precise tissue removal with minimal scarring.⁷

The first author's experience with the coblation system in tonsillectomy and a variety of other ENT applications prompted him, when faced with extensive, recurrent papillomata, to offer this form of treatment as an alternative to older methods, as none is known to be perfect and coblation offered the possibility of a favourable result.^{10,11}

Method

The first patient to undergo treatment using this technique was a 41-year-old woman living in

Ahmedabad, India, who presented with severe hoarseness and exertional dyspnoea. At another centre, she had previously undergone four procedures for laryngeal papillomata, involving removal of lesions by both cold steel dissection and laser techniques. All wands used are single use. They cost between £100 and £150 depending on model and distributor.

The patient was anaesthetized in the standard manner, using a microlaryngeal tube. The pre-operative view is shown in Figure 1; extensive papillomata can be seen on both vocal folds, including the anterior and posterior commissures. The appearance of the larynx at the end of the procedure was reassuringly normal, with no signs of charring or bleeding. The patient's recovery was uneventful, and no signs of oedema were seen on endoscopic examination the following morning. No antibiotics or steroids were used.

When reviewed two months post-operatively, the patient was found to have a good voice and no exertional dyspnoea. The laryngeal appearance at that time is shown in Figures 2 and 3. She remained well at six months follow up.

The second patient was a 38-year-old man treated at the Blackburn Royal Infirmary, UK, for extensive papillomata affecting the glottis and supraglottis. This patient had undergone three previous microlaryngoscopies, using CO₂ laser or cold steel dissection. An expandable laser laryngoscope was used to gain adequate exposure of the larynx. The patient was discharged home on the day of surgery, without complications. Again, steroids and antibiotics were not used. A mucosal wave was seen bilaterally at laryngeal stroboscopy four months post-operatively.

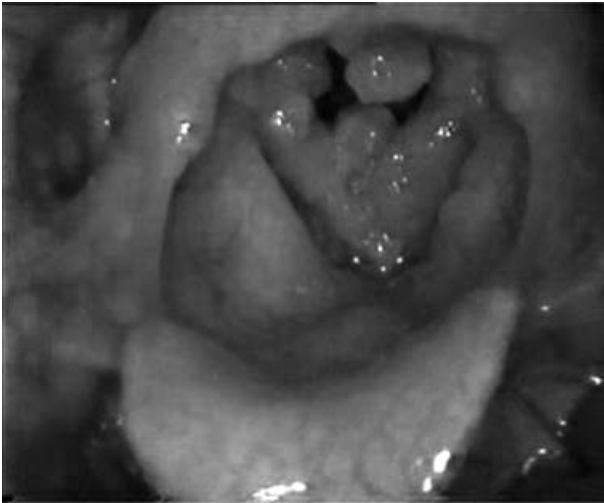


FIG. 1
Pre-operative appearance.

In the first case, an Evac 70 wand (Arthrocare, Sunnyvale, California, USA) delivering simultaneous saline irrigation and suction was used throughout, with an ablation setting of five and coagulation setting of three. By placing the wand near the lesions, the suction drew the papillomata onto the wand tip, where they were each ablated with short bursts of energy until no macroscopic disease was visible. No bleeding occurred at any stage and no physical contact pressure was applied to the underlying tissues. There was no disease present in the subglottis, which was fortunate as this particular wand was working at its maximum extent. No protection of the endotracheal tube was necessary, and care was taken to aspirate any and all saline from the glottis and trachea as the procedure progressed. It

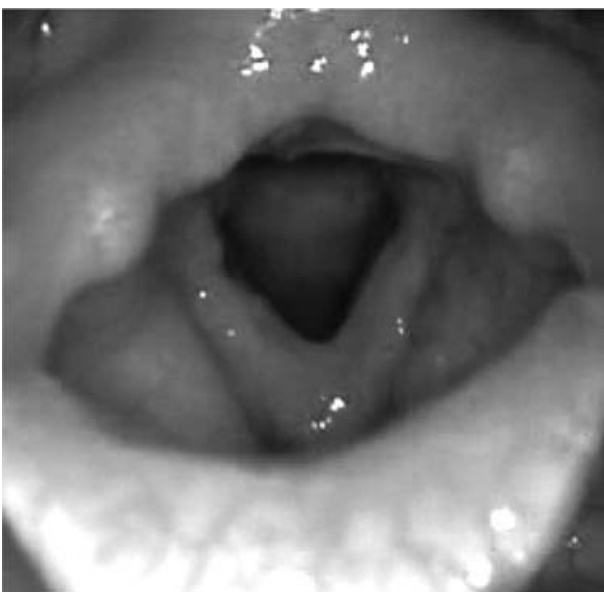

FIG. 2
Post-operative view in abduction.

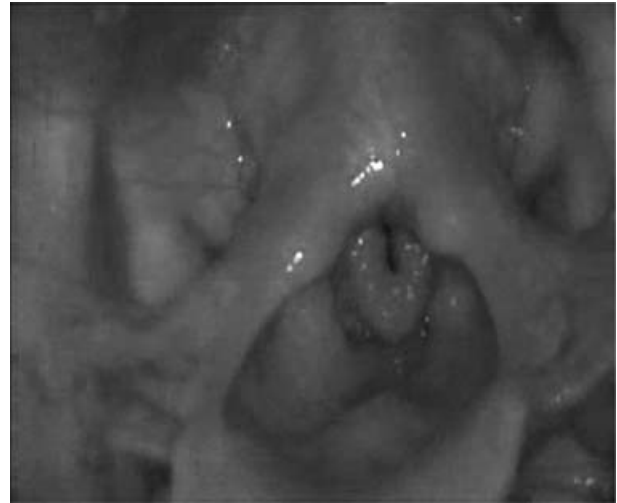


FIG. 3
Post-operative view on phonation.

was necessary to reposition the tube to gain access to the posterior commissure.

By the time of the second case, a new laryngeal wand had been produced, the EIC7070 (Arthrocare) and this was the model used. This wand was slimmer than the Evac 70, being 4 mm in diameter. It had a 30° bend at its distal tip and was 25 cm in length. This enabled work not only on the larynx but also on the trachea down to the carina. This new wand was also malleable; as a result, the optimum angle of application of the active tip electrodes onto the papillomata could be achieved. Again, when using this new wand, the tip was placed adjacent to the papillomata, sucking the lesions onto the tip. Following this, coblation energy was applied without pressure or damage to underlying tissues. A video clip of this wand in use is available for scrutiny on the Arthrocare website.¹²

Discussion

All existing methods of surgical removal of laryngeal papillomata have their drawbacks. Repeated surgery, whatever the method, is bound to result in fibrosis and scarring, with consequent effects on voice quality. Despite advances in laser technology, it is still difficult to avoid damage to underlying tissues. In one retrospective analysis of 17 patients with recurrent laryngeal papillomata treated with CO₂ laser removal, 10 patients were subsequently found to have developed laryngeal scarring. A further patient with tracheobronchial papillomatosis developed tracheal scarring following laser treatment, which necessitated laryngotracheal separation.⁷ Another series reported delayed laryngeal complications, including glottic webbing, interarytenoid scarring and arytenoid fixation, in 36 per cent of paediatric patients and 17 per cent of adult patients following CO₂ laser removal of recurrent laryngeal papillomata.⁸

The natural history of laryngeal papillomatosis is such that multiple procedures are often required for

long term management. Laryngeal scarring itself will not infrequently necessitate further surgical intervention, in patients who have already endured multiple laryngeal procedures.⁷

- **This paper reports the use of radiofrequency ablation (coblation) in the treatment of two adults with extensive laryngeal papillomatosis**
- **The advantages of this technique include minimal damage to underlying tissues and a bloodless field**
- **Further evaluation is required; however, this technique shows promise in the management of this difficult condition**

Laser surgery has its difficulties – it requires a fully educated operating theatre team, and, depending on local regulations, a laser tube may be required, limiting surgical access. On the other hand, surgery with cold steel or, more recently, the microdebrider, tends to be hampered by bleeding, limiting the view and adequacy of disease removal. This difficulty can be reduced to some extent by the application of adrenaline-soaked swabs or patties.

We found the coblator system to be helpful in a number of ways. A standard, fine bore microlaryngeal tube could be used. Adequate access was achieved using a conventional laryngoscope. Papillomata could be sucked onto the wand tip and ablated without physical trauma to the underlying tissues. The radiofrequency energy of this particular system has been reported to penetrate surrounding tissues to a depth of only 100 μm .¹³ One would therefore expect the local electro-thermal damage to surrounding tissues to be less than that encountered with suction diathermy or laser treatment.

Use of the disposable wand does, of course, introduce additional expense, but so too does use of laser tubes and microdebrider blades.

We are not suggesting that the coblator is the perfect therapy for laryngeal papillomata. However, our experience in these cases has been dramatic and indicates that there are strong grounds for further exploring this treatment for laryngeal papillomatosis and other related conditions. The authors intend to investigate this promising technique further, using tools such as voice recording analysis. Radiofrequency ablation does appear to satisfy the aims of surgical management of laryngeal

papillomatosis, as described by Irwin *et al.*, namely, facilitating a satisfactory airway and good voice in a relatively atraumatic fashion, thereby limiting the chance of distal papilloma seeding and subsequent scar formation.³

References

- 1 Bishai D, Kashima H, Shah K. The cost of juvenile-onset recurrent respiratory papillomatosis. *Arch Otolaryngol Head Neck Surg* 2000;**126**:935–9
- 2 Green GE, Bauman NM, Smith RJ. Pathogenesis and treatment of juvenile onset recurrent respiratory papillomatosis. *Otolaryngol Clin North Am* 2000;**33**:187–207
- 3 Irwin C, Pincott RJ, Bailey CM, Evans JNG. Juvenile laryngeal papillomatosis. *J Laryngol Otol* 1986;**100**:435–45
- 4 Myer CM 3rd, Willging JP, McMurray S. Use of a laryngeal micro resector system. *Laryngoscope* 1999;**109**:1165–6
- 5 Ossoff RH, Werkhaven JA, Dere H. Soft-tissue complications of laser surgery for recurrent respiratory papillomatosis. *Laryngoscope* 1991;**101**:1162–6
- 6 Perkins JA, Inglis AF Jr, Richardson MA. Iatrogenic airway stenosis with recurrent respiratory papillomatosis. *Arch Otolaryngol Head Neck Surg* 1998;**124**:281–7
- 7 Saleh EM. Complications of treatment of recurrent laryngeal papillomatosis with the carbon dioxide laser in children. *J Laryngol Otol* 1992;**106**:715–18
- 8 Crockett MD, McCabe FB, Shive JC. Complications of laser surgery for recurrent respiratory papillomatosis. *Ann Otol Rhinol Laryngol* 1987;**96**:639–44
- 9 Wetmore SJ, Key JM, Swen JY. Complications of laser surgery for laryngeal papillomatosis. *Laryngoscope* 1985;**95**:798–801
- 10 Timms MS, Temple RH. Coblation tonsillectomy: a double blind randomized controlled study. *J Laryngol Otol* 2002;**116**:450–2
- 11 Temple RH, Timms MS. Paediatric coblation tonsillectomy. *Int J Paed Otorhinolaryngol* 2001;**61**:195–8
- 12 http://www.arthrocareent.com/wt/page/int_physicians [Mid August 2006]
- 13 Woloszko J, Stalder KR, Brown IG. Plasma characteristics of repetitively-pulsed electrical discharges in saline solutions used for surgical procedures. *IEEE Trans Plasma Sci* 2002;**30**:1376–83

Address for correspondence:

Mr M S Timms,
Department of Otolaryngology,
Blackburn Royal Infirmary,
Infirmary Street,
Blackburn BB2 3LR, UK.

Fax: 01254 826151
E-mail: timms826@btinternet.com

Mr M S Timms takes responsibility for the integrity of the content of the paper.
Competing interests: None declared
