

# Submucosal Minimally Invasive Lingual Excision: An Effective, Novel Surgery for Pediatric Tongue Base Reduction

Stephen C. Maturo, MD, Capt, USAF, MC; Eric A. Mair, MD, Col, USAF, MC

**Objectives:** The aim of this study was to develop an effective single intraoral, minimally invasive technique to reduce the enlarged tongue base in children with obstructive macroglossia.

**Methods:** We present the anatomic dissection of fresh cadavers and a representative case series of children who underwent submucosal minimally invasive lingual excision (SMILE) with a plasma-mediated radiofrequency device (coblation) under intraoral ultrasonic and endoscopic guidance. Multiple anatomic dissections determined the relative location of the hypoglossal nerve and lingual neurovascular bundle in relation to removable tongue base musculature. A pediatric case series demonstrates the straightforward SMILE technique.

**Results:** Laboratory anatomic dissection and clinical lingual ultrasonography revealed the surgical safety borders for SMILE. The surgical safety and efficacy of SMILE is demonstrated by preoperative and postoperative clinical examinations and polysomnograms in children with obstructive macroglossia (such as Beckwith-Wiedemann and Down syndromes and tongue vascular malformation). Coblation submucosally removes excessive tongue base tissue through a small anterior tongue incision. SMILE was performed without excessive pain, bleeding, edema, infection, or tongue dysfunction.

**Conclusions:** SMILE is an effective novel operation that incorporates coblation with ultrasonography and endoscopic guidance for children who need tongue base reduction. Anatomic dissection and clinical cases demonstrate the potential for aggressive yet relatively safe tissue removal by this minimally invasive technique. SMILE also has significant potential for adults with obstructive sleep apnea due to a large tongue base.

**Key Words:** macroglossia, submucosal minimally invasive lingual excision, tongue base reduction.

## INTRODUCTION

In contrast to adults, children with obstructive sleep apnea (OSA) primarily benefit from surgical intervention. Tonsillectomy and adenoidectomy (T&A) is a popular and highly effective treatment for pediatric OSA with success rates exceeding 80%.<sup>1</sup> But what does one do when pediatric OSA persists despite T&A? Recalcitrant OSA cases frequently involve children with special needs or syndromes who have true or relative macroglossia. The pediatric alternatives are very limited. Compliance with long-term continuous positive airway pressure in children is poor, and pediatric tracheotomy, although the surgical gold standard, is usually the very last resort. Uvulopalatopharyngoplasty is not a panacea for the surgical treatment of sleep apnea in adults or children. Addressing the tongue and retro-lingual area is necessary in many patients.<sup>2</sup>

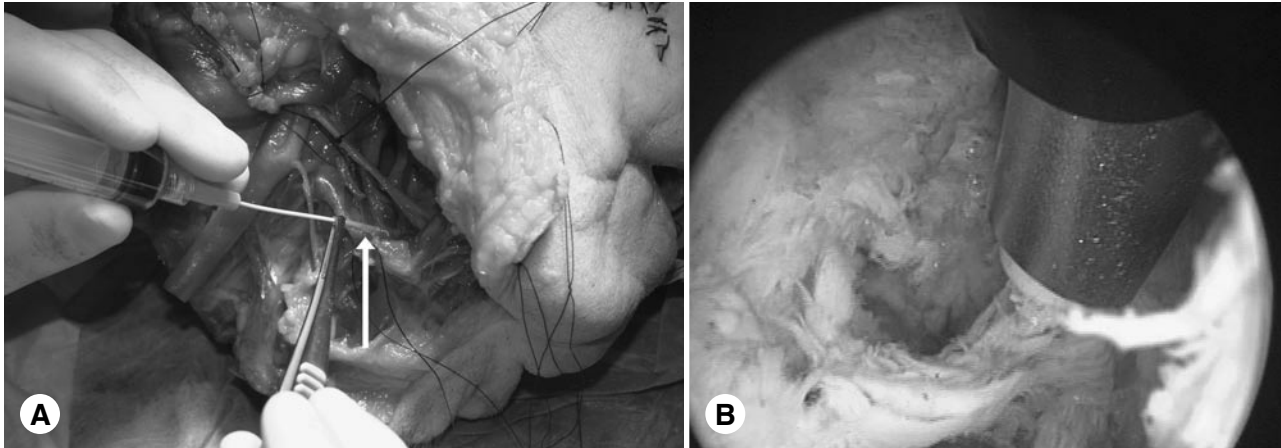
Tongue base reduction for OSA has received significant attention over the past decade. There are currently two types of surgical procedures for an en-

larged tongue base. The standard surgical procedures are invasive and directly remove a wedge of tongue muscle and mucosa. These are associated with significant morbidity, yet the results are generally effective.<sup>3-5</sup> Newer, less invasive procedures rely on either tongue repositioning or scarring with multiple surgeries. Unfortunately, the results are generally ineffective.<sup>6-8</sup> Multiple techniques have been performed to treat the retro-lingual area in both children and adults and include (from most to least invasive) midline glossectomy, skeletal advancement, hyoid suspension, genioglossus advancement, tongue suspension, and, most recently, temperature controlled radiofrequency volumetric reduction (TCRF). No one technique has been found to be consistently successful over the long term.

Drawbacks from the more invasive procedures include bleeding, swelling, and prolonged dysphagia. The least invasive procedure, TCRF, requires multiple treatments, does not remove tissue, is associated with abscess and edema, and has an unimpressive

From the Pediatric Otolaryngology Service, Department of Otolaryngology, Wilford Hall United States Air Force Medical Center, San Antonio, Texas. The opinions presented in this manuscript are those of the authors only and are not to be construed as representing the official view of the United States Air Force, Department of Defense, or United States Government.

**Correspondence:** Eric A. Mair, MD, Pediatric Otolaryngology, Charlotte EENT Associates, 6035 Fairview Rd, Charlotte, NC 28210; e-mail emair@ceenta.com.



**Fig 1.** Cadaver study. **A)** Lingual artery isolated in cadaver neck (arrow) in preparation for injection of methylene blue. **B)** Endoscopic view within midline cadaver tongue base during submucosal minimally invasive lingual excision (SMILE). Coblation removes up to 20 cm<sup>3</sup> of tongue base muscle while protecting lingual arteries and nerves.

long-term success rate.<sup>9</sup>

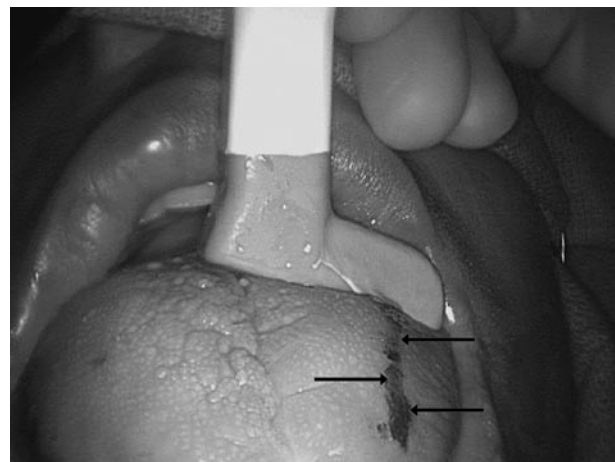
Robinson et al<sup>10</sup> introduced a submucosal tongue base excision technique for adults with OSA. They used a plasma-mediated radiofrequency device (coblation) under ultrasonic guidance.<sup>10</sup> The advantages of this technique include minimally invasive tissue removal with additional, adjacent scar formation by means of low-temperature ionization. The results were similar to those of the more invasive tongue wedge excision and had equivalent complication rates. The disadvantages of the technique of Robinson et al<sup>10</sup> include an invasive suprahyoid neck incision, difficulty with specialized cervical ultrasound techniques, inability to directly visualize the operative field, and a perceived need for lingual cavity closure. We simplified the technique to avoid a neck incision by placing a small stab incision in the anterior portion of the dorsal tongue. Our submucosal minimally invasive lingual excision (SMILE) technique avoids violating the floor of mouth musculature while removing lingual tissue under oral ultrasound and endoscopic guidance. We describe our experience with 4 representative pediatric patients with significant macroglossia and OSA in whom previous tongue base reduction techniques had failed.

#### METHODS AND MATERIALS

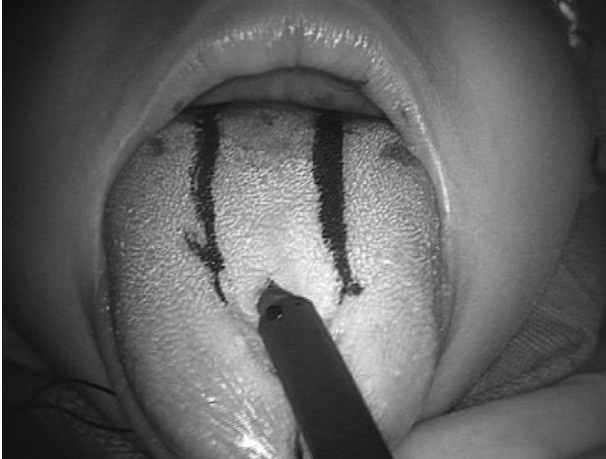**Cadaver Study.** Ten hypoglossal, lingual neurovascular bundles were dissected in 5 fresh adult cadaver heads in order to study the relative location of the hypoglossal nerve, lingual artery, and lingual nerve. Bilateral neck dissections traced both the lingual artery and the hypoglossal nerve in their entirety. Intraoral dissection also traced the lingual nerve in its entirety. Each lingual artery was isolated and injected with methylene blue dye to trace the

branches of the lingual artery as they approached the tongue base. The SMILE procedure, as outlined below, was performed on the cadaver tongues (Fig 1).

**Case Series.** The following representative case reports of pediatric SMILE illustrate the surgical technique. Parental informed consent is obtained. Children are treated while under general anesthesia through either a previously placed tracheotomy for macroglossia or via nasotracheal intubation. Each child receives intravenous steroids (as much as 10 mg of dexamethasone acetate) and antibiotics (10 mg/kg of intravenous clindamycin phosphate). After intubation, the oral cavity is gently brushed with 0.12% chlorhexidine gluconate oral rinse and a retraction suture is placed through the anterior midline tongue tip. A handpiece ultrasound probe then delineates and marks the course of the lingual arter-



**Fig 2.** Color Doppler ultrasonography maps out course of lingual arteries (between arrows). Hypoglossal and lingual nerves are lateral to lingual artery. SMILE dissection is directed at tongue base between lingual arteries. Anterior tongue retraction suture facilitates SMILE.

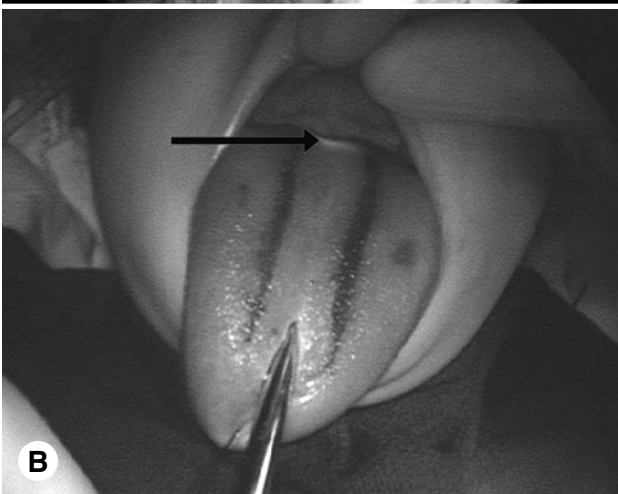
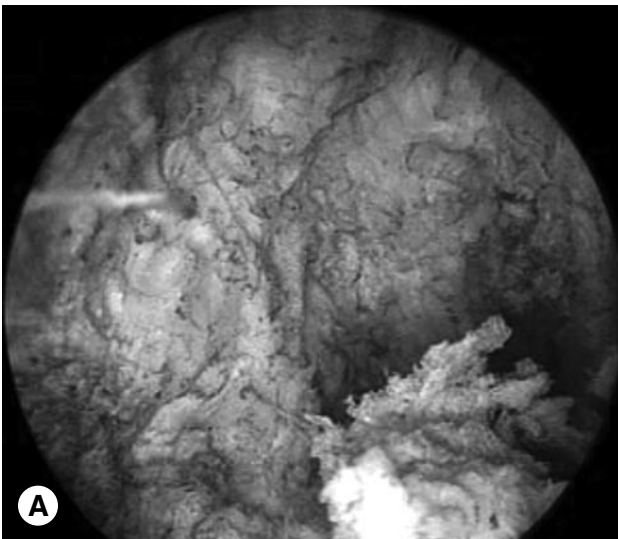


**Fig 3.** EVac 70 T&A Plasma Wand is placed inside tongue through anterior submucosal incision. Tactile palpation (along with ultrasonography and endoscopy) ensures relatively safe tongue base tissue removal.

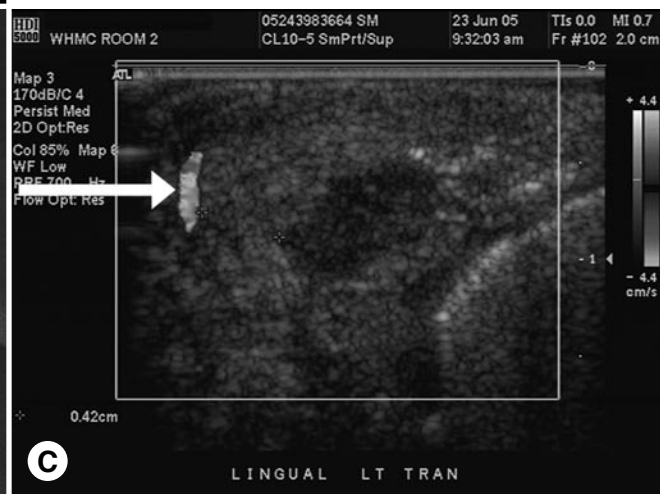
ies bilaterally (Fig 2). A midline incision is made approximately 2 cm from the tongue tip with blunt dissection to open the incision. An ArthroCare EVac

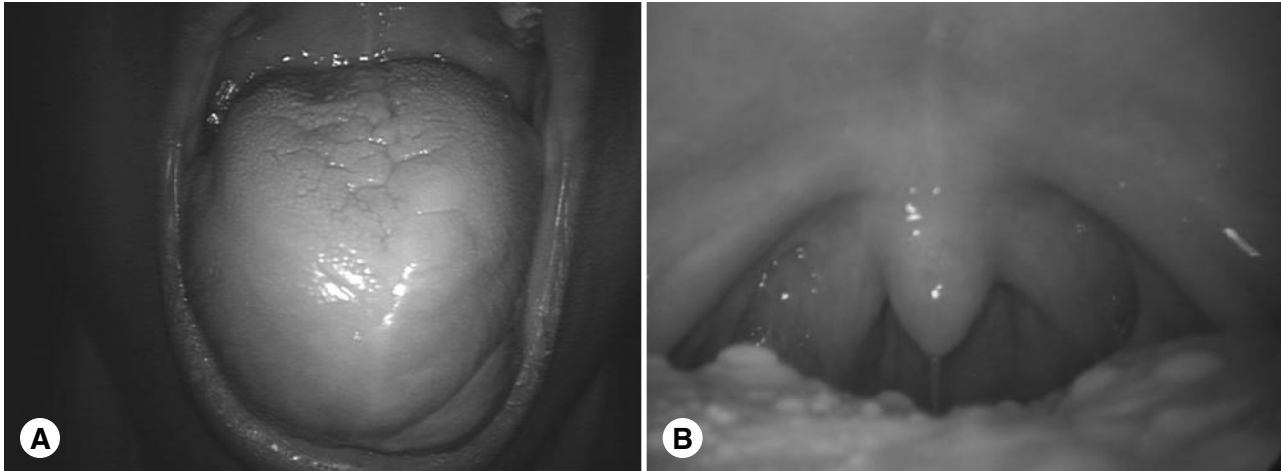
70 T&A Plasma Wand attached to the Coblator II Surgery System (ArthroCare Corporation, Austin, Texas) with coblator ablation at a setting of 9 is then inserted into the incision. With care taken to stay medial to the marked boundaries of the lingual artery, the coblator wand is advanced in the posterior direction and tissue is excised by moving the wand in a superior-to-inferior fashion by staying medial to the lingual arteries. The nonoperating hand palpates the tip of the coblator wand through the tongue mucosa (Fig 3).

Progress is monitored by intermittently removing the wand and inserting a 0° irrigating endoscope (Clear ESS, SLT, Montgomeryville, Pennsylvania) into the created cavity (Fig 4). The anterior tongue incision is not closed. After the operation, children are either extubated and monitored or intubated for less than 24 hours. Children receive intravenous dexamethasone acetate (1 mg/kg up to 10 mg) every 8 hours for a total of 3 doses and also intravenous clindamycin (30 mg/kg daily divided every 8



**Fig 4.** SMILE procedure. **A)** Endoscopic view of posterior tongue base immediately after SMILE. Note aggressive tissue excision and excellent hemostasis. **B)** Glow of light (arrow) from endoscope placed submucosally through small anterior tongue incision. Endoscopic views extend submucosally back to vallecular area. **C)** Doppler ultrasound scan clearly identifies intact lingual artery (arrow) next to SMILE cavity created by tongue base tissue resection.





**Fig 5.** (Patient 2) SMILE. **A)** Preoperative view of macroglossia in teenager with Beckwith-Wiedemann syndrome and obstructive sleep apnea. **B)** Postoperative view 3 weeks after SMILE procedure. Smaller tongue base permits visualization of uvula and tonsillar fossae. Tongue is soft and mobile.

hours). Once extubated, each patient is started on a regular, soft diet. Children are observed for less than 72 hours and discharged home with 7 days of oral antibiotics, steroids, and acetaminophen with or without codeine phosphate. Follow-up may include interdisciplinary care with a speech therapist or dentist as necessary.

#### RESULTS

*Cadaver Study.* Cadaver dissections confirmed that the lingual artery is consistently medial to both the hypoglossal and lingual nerves. Fortunately, the lingual artery is positioned in a relatively lateral position in the posterior tongue base, in which surgical dissection is most critical. This position permits the large amount of tongue muscle excision that is usually required in this area. As much as 20 cm<sup>3</sup> of tongue base tissue is removed. This equates to 15% to 20% of the adult tongue volume.

*Patient 1.* Patient 1 was a tracheotomy-dependent 16-month-old girl with Beckwith-Wiedemann syndrome and macroglossia. She had required a tracheotomy in the first month of her life because of obstructive macroglossia. The obstruction persisted despite a subsequent central anterior tongue wedge resection at age 9 months. She also had significant dysphagia, oral incompetence, and aspiration secondary to the macroglossia. She required a percutaneous endoscopic gastrostomy tube. Decannulation trials failed because of persistent obstructive macroglossia.

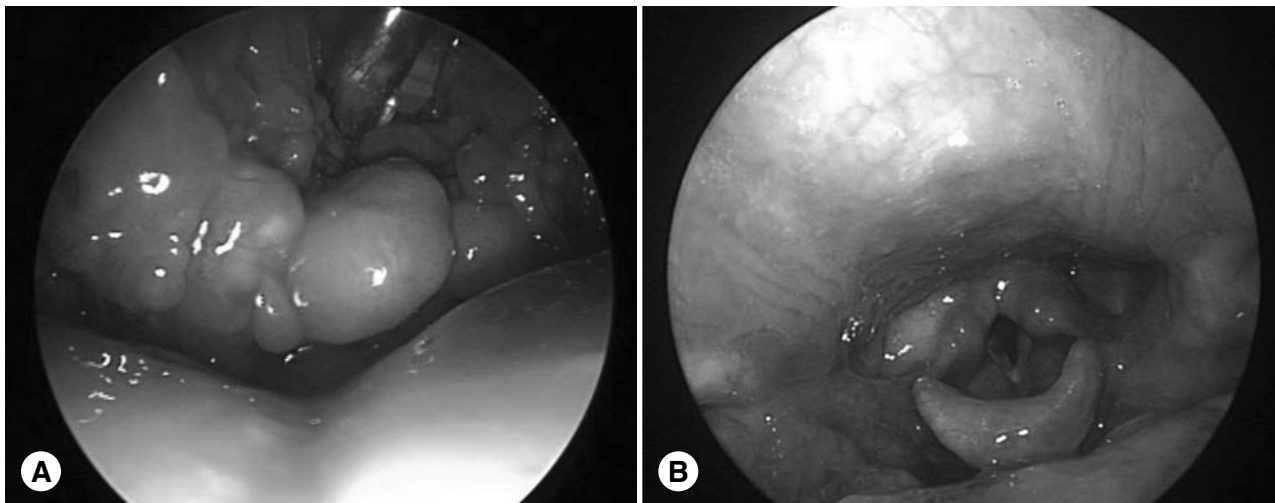
She underwent the SMILE procedure without complication and was discharged 48 hours after surgery. Six weeks after operation she was successfully decannulated and for the first time in her life was able to take food by mouth without aspiration. Also, it was the first time she was able to communicate

orally with her family. Her tongue was fully mobile, and there was no evidence of dysarthria. She now sleeps without snoring or witnessed apneas. The tracheotomy and percutaneous endoscopic gastrostomy stomas are closed.

*Patient 2.* Patient 2 was a 14-year-old girl with Beckwith-Wiedemann syndrome, macroglossia, and obstructive sleep apnea despite multiple tongue surgeries. She had previously undergone tracheotomy and multiple tongue wedge excisions. She was decannulated but suffered from dysarthria and excessive daytime fatigue. Preoperative polysomnography (PSG) showed an apnea-hypopnea index (AHI) of 10 events per hour and a lowest oxygen desaturation (LSAT) of 85%.

Her SMILE operation was uneventful, and she was extubated less than 24 hours after operation. A regular diet was tolerated without difficulty, and pain was minimal. Routine follow-up did not reveal any alteration in tongue mobility, sensation, or function. Postoperative PSG done at 4 months revealed an AHI of 0.9 and an LSAT of 86%. Dysarthria, daily fatigue, and nighttime snoring were significantly diminished (Fig 5).

*Patient 3.* Patient 3 was an 11-year-old girl with Down syndrome with obstructive macroglossia and lingual tonsillar hypertrophy. She had previously undergone T&A, uvulopalatopharyngoplasty, and multiple TCRF applications to the tongue base for her OSA. Her parents reported significant snoring and witnessed apneas along with school inattentiveness. Preoperative PSG revealed an AHI of 10 and an LSAT of 76%. Physical examination revealed a prominent tongue base along with enlarged lingual tonsils. A nasotracheal tube, an oral rubber bite block, and an anterior tongue retraction suture were



**Fig 6.** (Patient 3) Endoscopic coblation lingual tonsillectomy and SMILE. **A)** Preoperative intubated view of hypopharynx of child with Down syndrome. Note enlarged lingual tonsils and hypertrophied tongue base. Both entities are addressed separately with coblation wand. Lingual tonsils are excised intraorally with help of 70° sinus endoscope. If SMILE were performed without concomitant lingual tonsillectomy, obstructive sleep apnea would likely persist. Careful evaluation of lingual tonsils prior to SMILE is important. **B)** One-week-postoperative endoscopic view. Note smaller tongue base and absent lingual tonsils. Child no longer has obstructive sleep apnea.

placed. The coblator wand was gently curved, and a standard 70° 4-mm sinus endoscope was used to perorally view the enlarged lingual tonsils. The lingual tonsils were directly ablated down to tongue mucosa with coblator settings identical to those used with SMILE. SMILE was then performed in the standard fashion (Fig 6). The blood loss was minimal. The postoperative course was uneventful and involved a planned prophylactic overnight intubation. She demonstrated full tongue mobility with no alterations in speech or swallow on routine follow-up. A sleep study done 3 months after the operation revealed an AHI of 0.2 and an LSAT of 93%. Her parents have reported no snoring or apnea and have reported improved school results.

**Patient 4.** Patient 4 was a 9-year-old girl with macroglossia due to vascular malformation. She presented with a persistent right tongue vascular malformation and notable dysphagia with intermittent episodes of tongue edema. She had multiple glosal interstitial neodymium:yttrium-aluminum-garnet laser treatments over the past year without improvement in her symptoms. No OSA was noted on PSG. She underwent SMILE with coblation to the vascular mass. Her blood loss was minimal, and her tongue mass receded after surgery. She had no recurrent episodes of tongue edema, and her dysphagia has resolved. Her speech intelligibility is improved. Her tongue is fully mobile and has normal sensation.

#### DISCUSSION

Severe pediatric OSA due to macroglossia is a challenging surgical problem that has perplexed

otolaryngologists for many years. Compliance with continuous positive airway pressure approaches 50% in adults and is even lower in children. A tight-fitting mask creates problems with comfort, nasal congestion, crusting, epistaxis, eye irritation, and difficulty adapting to pressure.<sup>11</sup> Although pediatric tracheotomy is the gold-standard surgical therapy, it is associated with multiple complications in children, including pneumomediastinum (43%), pneumothorax (17%), bleeding (7%), tracheal stenosis (6%), obstructed tube (14%), and accidental decannulation (16%).<sup>12</sup>

Coblation technology provides the ability to remove tissue at a low temperature, thereby causing less tissue destruction and resulting edema. Previously described techniques for tongue base treatment include use of electrocautery or laser application, which causes significant postoperative pain, edema, and dysphagia.<sup>3-5</sup> The advantages of SMILE include tissue bulk removal that leaves the mucosal surface intact, thus significantly decreasing the postoperative odynophagia, edema, and dysphagia in comparison to those following mucosal destructive techniques. The SMILE technique promotes the minimally invasive concept by making a small intraoral tongue incision rather than a suprahyoid neck incision that violates the floor of mouth musculature and fascial planes and puts the hypoglossal and lingual nerves at greater risk.<sup>10</sup> Although SMILE is a contaminated intraoral procedure, no postoperative infections were noted. The tongue is resistant to infection because of the increased intraoral vasculature and the copious intraoperative endoscopic tongue ir-

rigation and postoperative antibiotics used.

The greatest intraoperative concern for SMILE is damage to the lingual artery or one of its terminal branches. Previous studies have shown, and our dissections have confirmed, that the lingual artery runs laterally along the tongue base and that it is at a relatively consistent distance away from the foramen cecum in an inferior and lateral direction.<sup>13,14</sup> Intraoperative use of ultrasonography and endoscopy provides an added margin of safety. Although we choose to use ultrasonography and endoscopic guidance, this is not mandatory. If the surgeon stays within 1 cm of the midline tongue posterior to the foramen cecum, there is minimal risk of hemorrhage.

Several intraoperative “pearls” facilitate the SMILE procedure. Color Doppler ultrasound location of the lingual arteries is more beneficial than using a standard handheld audio Doppler probe. Ultrasonography provides a relatively simple and accurate mapping of each lingual artery and is used to identify the proximity of our coblator wand to the lingual artery and its branches. A second “pearl” is the use of a sturdy anterior tongue retraction suture to help gain access to the posterior tongue base. Full manual tongue protrusion facilitates SMILE. Third, the use of irrigating endoscopy, in which normal saline solution is irrigated into the cavity and suctioned, results in a clear submucosal picture of the entire operated lingual cavity. This helps the surgeon find locations in the cavity from which more tissue can be removed. Care must be taken to ensure that irrigation and coblated tissue are constantly flowing through the suction tubing of the wand. If the handpiece is clogged, the wand is immediately removed and the suction is unclogged. If the irrigation and suction system does not flow, excessive heat may damage the surrounding tissue. The coblator T&A wand is preferred, as it has a larger suction port compared with other wands. Fourth, the SMILE technique is also a “tactile” procedure. Although we use the endoscope to intermittently visualize the operated cavity, tissue removal may be done without direct visualization. The nondominant hand should palpate the tip of the coblator wand as it proceeds posterior in the submucosal plane. Manipulating the coblator in a sagittal plane rather than in a horizontal or “side-to-side” manner will aid in avoiding the lingual artery. Any unexpected bleeding is controlled with direct pressure. Finally, we found that if bleeding occurs that cannot be controlled with direct manual compression, applying FloSeal (Baxter International Inc, Deerfield, Illinois) directly through the incision into the submucosal cavity followed by pressure will stop the bleeding without postoperative

complications. Careful intraoral ultrasound guidance avoids bleeding; most cases have less than 10 mL of blood loss. Despite the tongue’s increased vascularity, hematoma has not been a problem with SMILE, likely because of the inherent compressive strength of the tongue musculature. The initial tongue incision functions as a drain in the early postoperative period. No anticoagulative medications are given in the preoperative and perioperative period.

The application of the SMILE technique was limited to children in this case series, yet we also perform the procedure successfully in adults with OSA and tongue base obstruction. Early on, we were cautious in our postoperative care, as we were unsure of the degree of postoperative edema that would occur with such aggressive tissue removal. There was no significant tongue base swelling, and in fact, we have already started successfully extubating the patient directly after the procedure in the operating room. We believe that this is a procedure that should be carried out in the operating room. General anesthesia provides a secure airway with no gag reflex, permits more aggressive base of tongue tissue removal, and ensures a controlled setting should intraoperative bleeding take place.

The limitations of this clinical study include limited follow-up in a small number of patients. This is a new technique carried out on a population of children with continuing macroglossia despite previous surgical attempts at correction. Preoperative and postoperative volumetric magnetic resonance imaging tongue measurements would have been helpful in documenting the tissue removal. However, magnetic resonance imaging studies in children, especially those with decreased mental faculties, can be a challenge to obtain, given the necessity for sedation and close monitoring. In fact, the pediatric tongue base studies in the literature are case series with limited imaging study follow-up. The lack of long-term follow-up is also an inherent weakness when any new technique is described, as initial successes may not be permanent or unforeseen complications may not manifest until long after healing has occurred. One concern is the aggressive tissue removal that SMILE provides at the tongue base and what possible effects this has on tongue mobility, swallowing, and speech. We have found no permanent complications. We believe that it is unlikely that this will be a long-term problem, because of the muscular redundancy that both the intrinsic and extrinsic tongue muscles provide and the fact that the muscles remain intact laterally. Of note, however, we have found a temporary decrease in post-SMILE tongue protrusion in some adult patients with OSA.

This is likely due to the planned partial excision of the genioglossus muscle. The tongue has a tremendous functional ability to respond to changes in size. SMILE completely preserves tongue tip musculature, important for articulation and other fine motor movements.

### CONCLUSIONS

Pediatric OSA due to macroglossia is a challenging surgical dilemma. Medical measures are poorly tolerated. Tracheotomy effectively bypasses the obstruction, but is not an acceptable long-term solution for many families. External wedge resections are associated with considerable morbidity. Minimally invasive procedures such as TCRF and

tongue suspension are usually ineffective. SMILE combines the aggressive tongue muscle excision of external resection with the scar induction of other minimally invasive procedures. Aggressive tongue base surgery is challenging and should only be performed by experienced surgeons able to recognize and treat potential complications. The side effects of bleeding, edema, pain, infection, and dysfunction are minimized, and the early results are favorable. Large multi-institutional trials are recommended to evaluate the long-term effects of SMILE. Careful preoperative evaluation with the focus on lingual tonsillar hypertrophy and/or tongue base muscular hypertrophy is essential. Coblation can effectively remove both enlarged lingual tonsils and hypertrophic tongue base musculature.

### REFERENCES

- Guilleminault C, Li KK, Khramtsov A, Pelayo R, Martinez S. Sleep disordered breathing: surgical outcome in prepubertal children. *Laryngoscope* 2004;114:132-7.
- Fujita S, Conway WA, Zorick FJ, et al. Evaluation of the effectiveness of uvulopalatopharyngoplasty. *Laryngoscope* 1985;95:70-4.
- Mickelson SA, Rosenthal L. Midline glossectomy and epiglottidectomy for obstructive sleep apnea syndrome. *Laryngoscope* 1997;107:614-9.
- Fujita S, Woodson BT, Clark JL, Wittig R. Laser midline glossectomy as a treatment for obstructive sleep apnea. *Laryngoscope* 1991;101:805-9.
- Woodson BT, Fujita S. Clinical experience with lingual-plasty as part of the treatment of severe obstructive sleep apnea. *Otolaryngol Head Neck Surg* 1992;107:40-8.
- Kuhnel TS, Schurr C, Wagner B, Geisler P. Morphological changes of the posterior airway space after tongue base suspension. *Laryngoscope* 2005;115:475-80.
- Li KK, Powell NB, Riley RW, Guilleminault C. Temperature-controlled radiofrequency tongue base reduction for sleep-disordered breathing: long-term outcomes. *Otolaryngol Head Neck Surg* 2002;127:230-4.
- Stuck BA, Kopke J, Hormann K, et al. Volumetric tissue reduction in radiofrequency surgery of the tongue base. *Otolaryngol Head Neck Surg* 2005;132:132-5.
- Pazos G, Mair EA. Complications of radiofrequency ablation in the treatment of sleep-disordered breathing. *Otolaryngol Head Neck Surg* 2001;125:462-7.
- Robinson S, Lewis R, Norton A, McPeake S. Ultrasound-guided radiofrequency submucosal tongue-base excision for sleep apnoea: a preliminary report. *Clin Otolaryngol Allied Sci* 2003;28:341-5.
- Anstead M, Phillips B, Buch K. Tolerance and intolerance to continuous positive airway pressure. *Curr Opin Pulm Med* 1998;4:351-4.
- Kremer B, Botos-Kremer AI, Eckel HE, Schlondorff G. Indications, complications, and surgical techniques for pediatric tracheostomies — an update. *J Pediatr Surg* 2002;37:1556-62.
- Lauretano AM, Li KK, Caradonna DS, Khosta RK, Fried MP. Anatomic location of the tongue base neurovascular bundle. *Laryngoscope* 1997;107:1057-9.
- Guan J, Yin S, Yi H, et al. Anatomic characteristics and relationship of lingual artery and hypoglossal nerve with tongue base [in Chinese]. *Lin Chuang Er Bi Yan Hou Ke Za Zhi* 2005;19:108-11.